

Patient	MR. JOHN DOE	Pt ID	31016	Acc#	
DoB	Sep 24,1948	Sex	M	Age	61
Body	HED	Body	CT	#Imgs	193
Referring		Study Time (local)	Nov 05,2009 22:54		
Radiologist		Receive Time (CST)	Nov 06,2009 06:47		

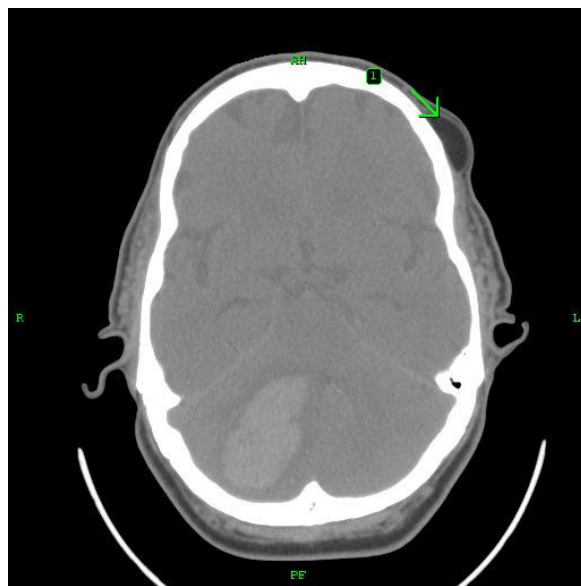
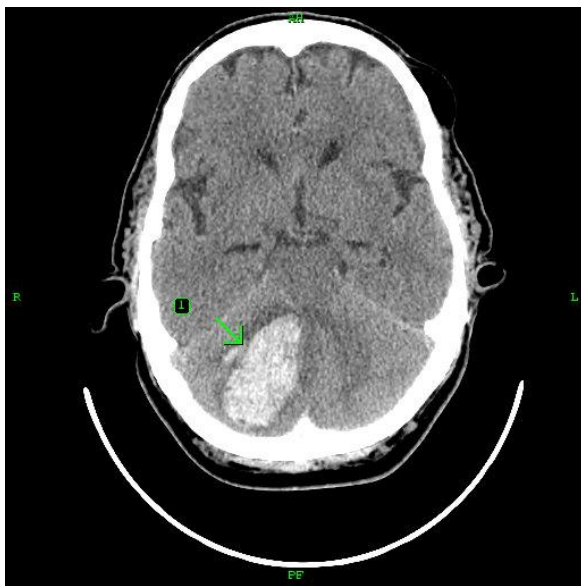
Observation

Clinical History: SOB, hypertension

The study is somewhat limited due to patient motion artifact. There is a hyperdensity at the right cerebellum measuring 5.7 x 3.5 cm in its widest anteroposterior and transverse dimensions with minimal surrounding edema. It exhibits mass effect with effacement of the 4th ventricle. Ventricles are not dilated. Midline structures are maintained. The CSF spaces in the cerebrum are prominent consistent with volume loss. Punctate hypodensities are noted in both thalamus and right basal ganglia which may represent chronic lacunar infarcts. There is nonspecific low attenuation in the deep white matter and periventricular regions suggestive of microvascular ischemic change. No extra-axial fluid collections is seen to the sensitivity of this artifact limited study. There is a well-defined hypodensity of fat attenuation in the left frontal scalp measuring 2.6 x 1 cm, likely representing lipoma. Mucosal thickening is seen in the ethmoid air cells. Rest of the visualized paranasal sinuses, mastoids and orbits are intact.

Impression

Limited study due to patient motion artifact. Acute hemorrhage in the right cerebellum with effacement of the 4th ventricle. No herniation syndrome and hydrocephalus at this time. Other findings as above. Follow up is recommended as clinically indicated.



PRELIMINARY REPORT: This is a preliminary report only. It is meant to focus on emergent management and life threatening conditions and will be entirely superseded by a final report.

QUALITY ASSURANCE: Please notify us of any significant discrepancies between this report and the final report by faxing both reports to 877-247-XRAY.

CONFIDENTIALITY STATEMENT: The information contained herein is legally privileged and confidential information intended only for the addressee. If you are not the intended recipient, any dissemination, distribution or any action taken, or omitted to be taken in reliance on it is prohibited. If you have received this message in error, please immediately notify the sender. Thank you for your cooperation.